



Automated Gonioscopy Clinical Cases


GS-1 Gonioscope

Contents

Contributing professionals	1
Introduction	2
Clinical cases	
Clinical evaluation	3
Surgical evaluation	5

Contributing professionals

Prof. Carlo E. Traverso, MD



Ophthalmology Dept, San Martino Hospital, Genova, Italy
Professor of Ophthalmology
Chairman of Clinica Oculistica University of Genova
Ospedale Policlinico San Martino
AAO Achievement Award, FARVO
President, EU EYE
Chairman, EGS Foundation Board
Medical director, FBOMJ Eye Bank of Genova
Executive Committee Member, Istituto David Chiossone Genova

Assist. Prof. Luis Abegão Pinto, MD, PhD



Ophthalmology Dept, Hospital Santa Maria, Lisbon, Portugal
Prof. Luís Abegão Pinto is the Head of the Glaucoma Clinic of the Department of Ophthalmology of Portugal's largest Hospital (Hospital Santa Maria) and serves as Assistant Professor of Ophthalmology at the Faculty of Medicine of Lisbon University, Portugal. He has authored or co-authored 50 indexed, peer-reviewed papers in Glaucoma. He is actively engaged in a number of scientific ophthalmological societies, including the European Glaucoma Society (EGS) and European Vision and Eye Research (EVER).


Assoc. Prof. Vikas Chopra, MD



Associate Professor, Ophthalmology
David Geffen School of Medicine at UCLA
Steward and Hildegard Warren Endowed Chair
Doheny Eye Institute
Principal Investigator, Doheny Image Reading Center
Medical Director, UCLA Doheny Eye Centers - Pasadena


60+ Peer-reviewed publications
AAO Achievement Award
Active Member: AAO, AGS, ABO

Introduction



The Gonioscope was developed to capture the entire 360 degrees of the angle using a unique 16 surface multi-mirrored prism lens. By optimizing the multimirror prism lens, a white LED is projected into the angle, simulating indirect static gonioscopy. Captured images can be stitched together to provide a view of the entire angle to support angle assessment and clinical findings.

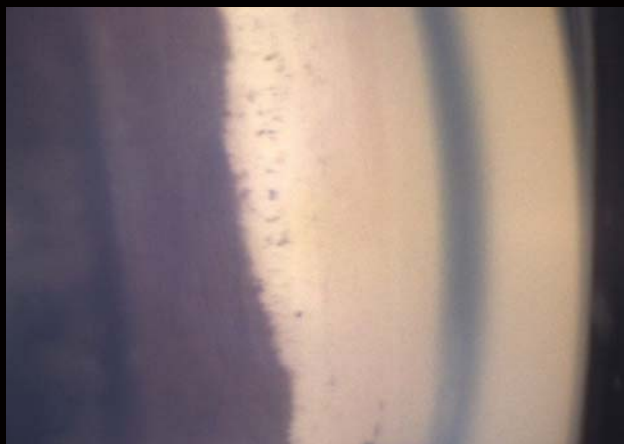
Width of the angle



Open ← → Closed

Clinical evaluation

Synechia^{*1}



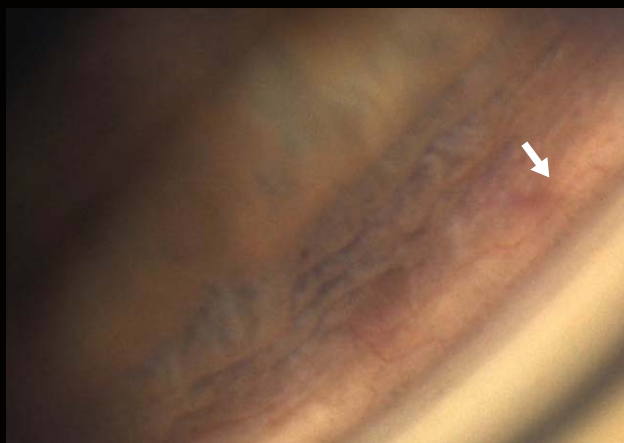
Comment
Closed angle
Trabecular meshwork is not visible.

Iris processes^{*2}

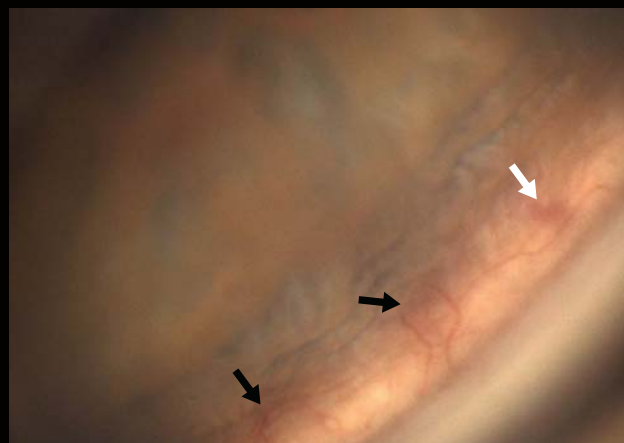


Comment
This is different from synechia.

Neo-vessels^{*2}



March 2018

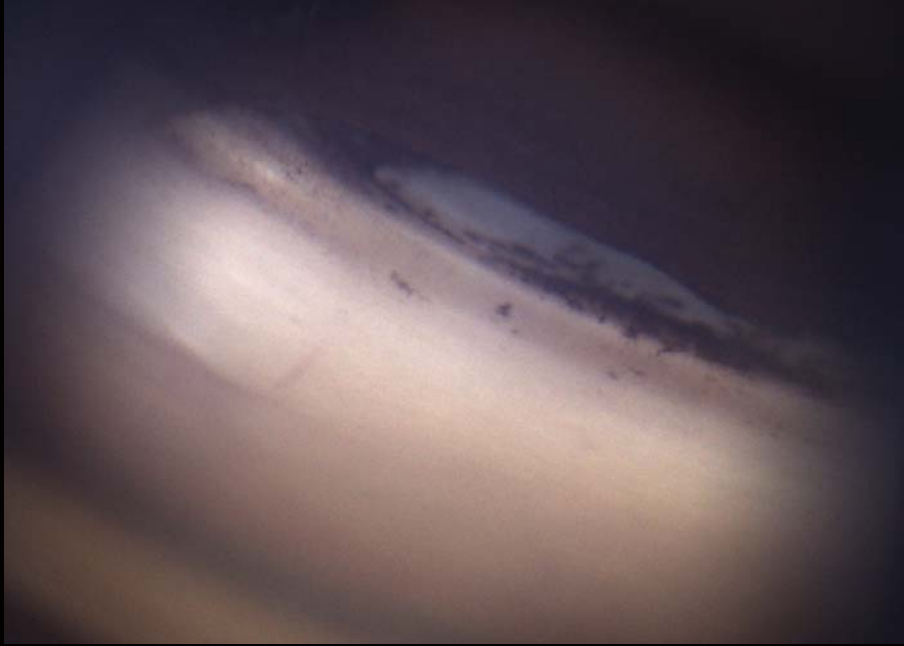

August 2018

Comment
White arrow : same vessel in both pictures
Black arrow : increased neovascularization, indicating progressive disease

*1 Images courtesy of Prof. C. E. TRAVERSO, MD, Clinica Oculistica, Di.N.O.G.M.I., University of Genova - Ospedale Policlinico S. Martino, Italy
*2 Images courtesy of Assist. Prof. Luis Abegão Pinto, MD, PhD, University of Lisbon, Portugal

Angular recession^{*1}



Comment

Cyclodialysis + Iridodialysis with sclera visible through cleft

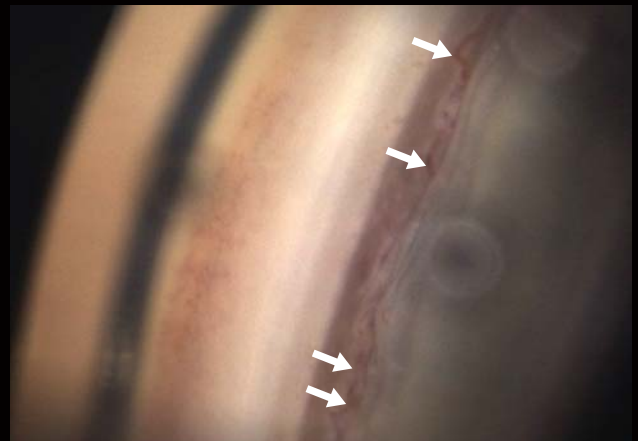
Angle closure^{*2}



Comment

Minor gap between the full length synechia

Sea-serpent^{*2}



Comment

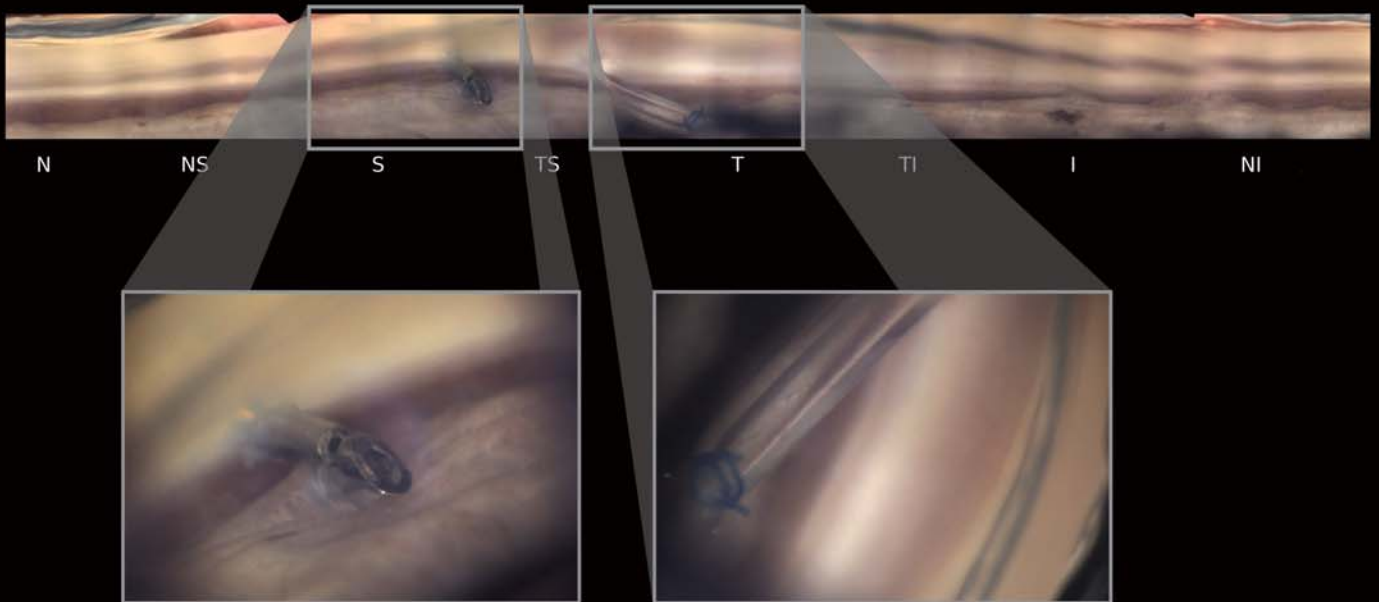
A physiological vessel circling the iris, not to be confused with neovascularization

^{*1} Images courtesy of Vikas Chopra, MD, Doheny Eye Institute, UCLA, USA

^{*2} Images courtesy of Assist. Prof. Luis Abegão Pinto, MD, PhD, University of Lisbon, Portugal

Surgical evaluation

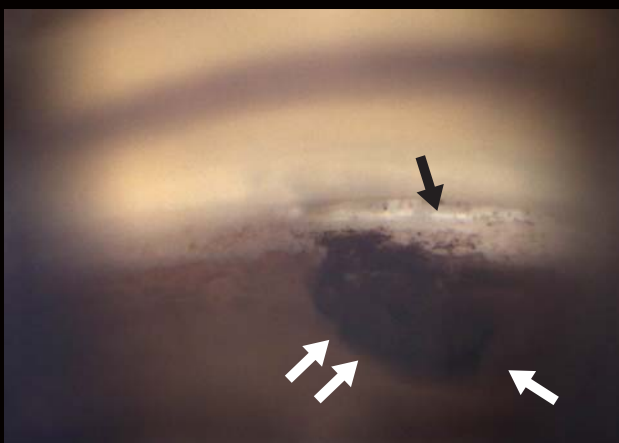Drainage system implantation^{*1}



Comment

Linear stitching and individual images


Trabeculectomy^{*2}



Comment

Black arrow: Scleral window
White arrows: Iridectomy beneath the scleral hole

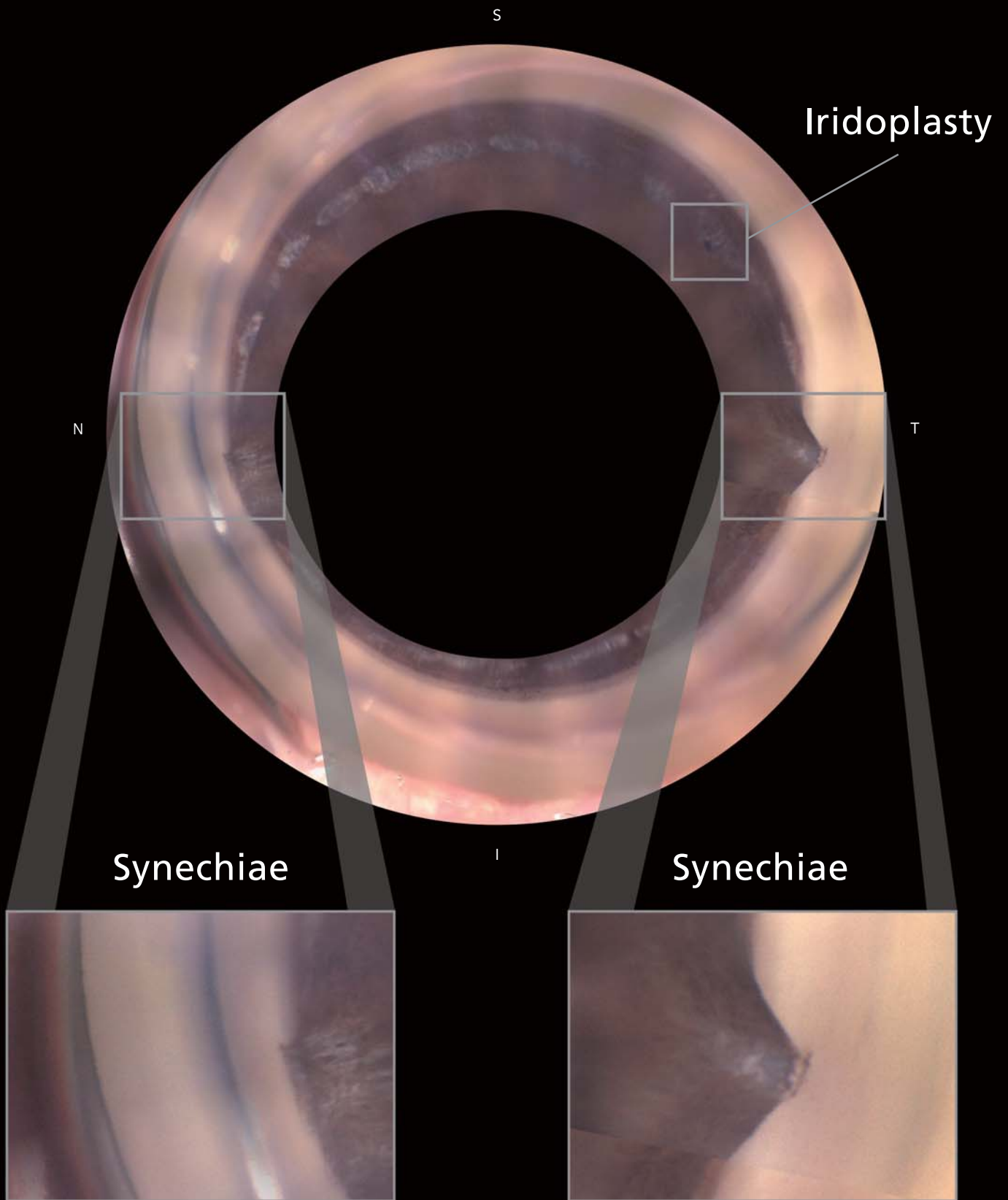
Post-vitreous surgery^{*2}



Comment

Silicone oil covering the entire superior angle

^{*1} Images courtesy of Prof. C. E. TRAVERSO, MD, Clinica Oculistica, Di.N.O.G.M.I., University of Genova - Ospedale Policlinico S. Martino, Italy
^{*2} Images courtesy of Assist. Prof. Luis Abegão Pinto, MD, PhD, University of Lisbon, Portugal



Surgical evaluation

Phakic IOL implantation ^{*1}




Comment

White arrow: Haptic of phakic IOL

Black arrows: Epithelial ingrowth covering the angle


MIGS device 1 ^{*2}



Comment

Trabecular bypass microstent
within Schlemm's canal

MIGS device 2 ^{*1}



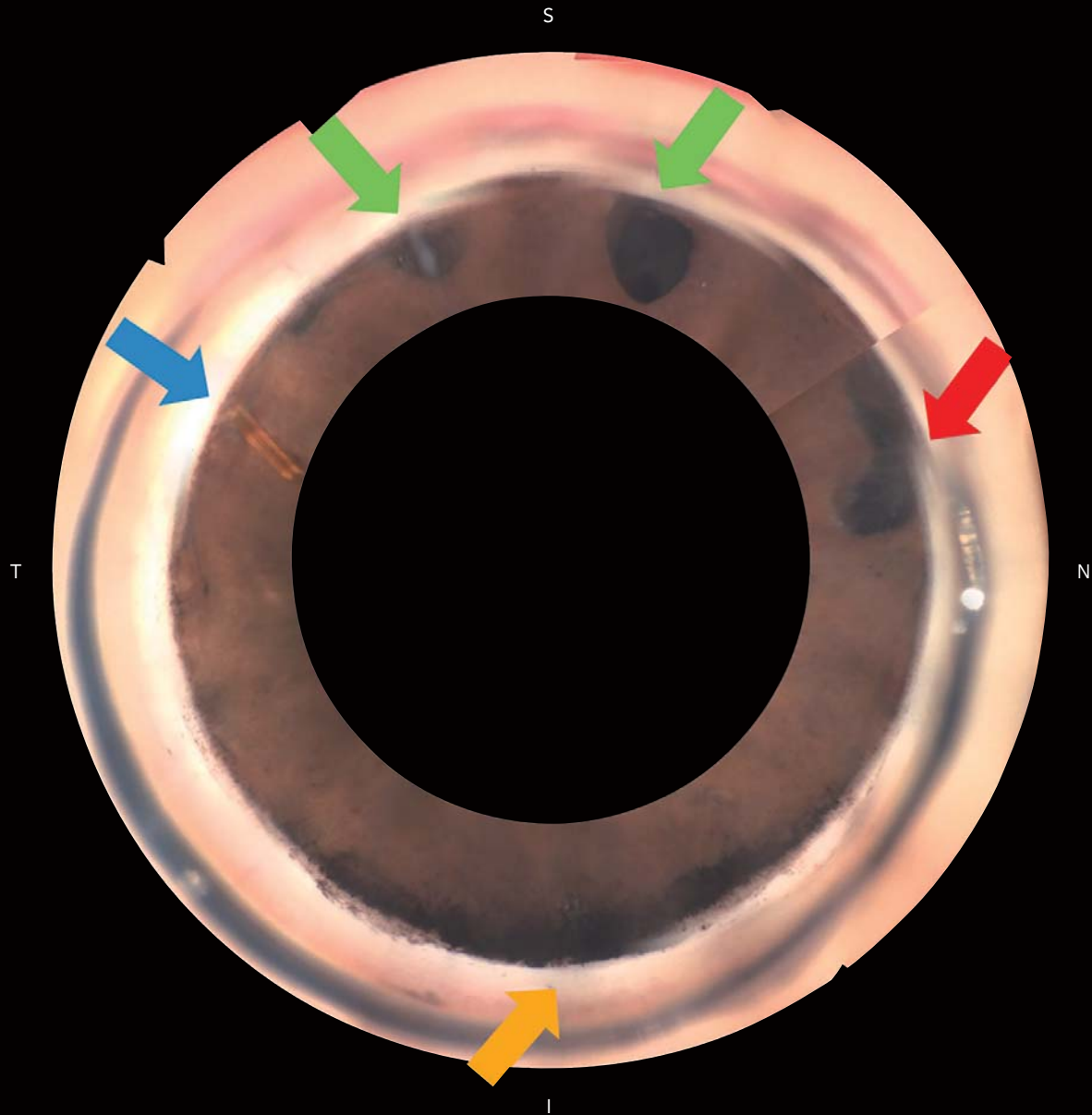
Comment

Focusing on the device

^{*1} Images courtesy of Assist. Prof. Luis Abegão Pinto, MD, PhD, University of Lisbon, Portugal

^{*2} Images courtesy of Vikas Chopra, MD, Doheny Eye Institute, UCLA, USA

Clinical and surgical evaluation



Comment

Blue arrow: MIGS implant

Green arrows: Trabeculectomy ostium

Orange arrow: Pigment deposit inferiorly

Red arrow: Iris torn from the root

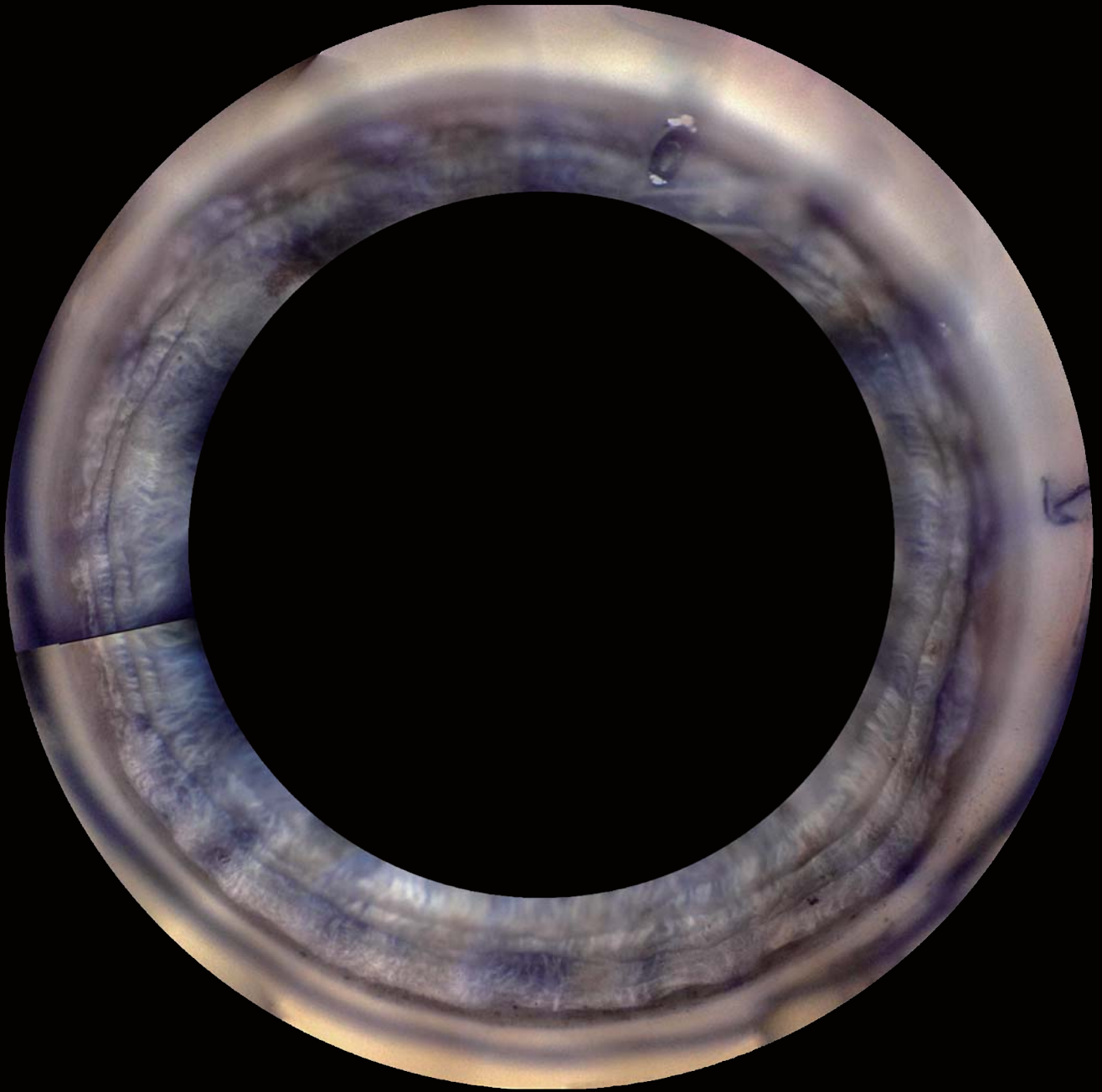


Image courtesy of Prof. C. E. TRAVERSO, MD, Clinica Oculistica,
Di.N.O.G.M.I., University of Genova - Ospedale Policlinico S. Martino, Italy

Brochure and listed features of the device are intended for non-US practitioners.



Eye & Health Care

NIDEK CO., LTD.

HEAD OFFICE
(International Div.)
34-14 Maehama,
Hiroishi-cho, Gamagori,
Aichi 443-0038, JAPAN
TEL: +81-533-67-8895
URL: www.nidek.com
[Manufacturer]

TOKYO OFFICE
(International Div.)
3F Sumitomo Fudosan Hongo
Bldg., 3-22-5 Hongo, Bunkyo-ku,
Tokyo 113-0033, JAPAN
TEL: +81-3-5844-2641
URL: www.nidek.com

NIDEK INC.
47651 Westinghouse Drive,
Fremont, CA 94539, U.S.A.
TEL: +1-510-226-5700
+1-800-223-9044
(US only)
URL: usa.nidek.com

NIDEK S.A.
Europarc,
13 rue Auguste Perret,
94042 Créteil, FRANCE
TEL: +33-1-49 80 97 97
URL: www.nidek.fr

NIDEK TECHNOLOGIES S.R.L.
Via dell'Artigianato,
6/A, 35020 Albignasego (Padova),
ITALY
TEL: +39 049 8629200 / 8626399
URL: www.nidektechnologies.it

NIDEK (SHANGHAI) CO., LTD.
Rm3205, Shanghai Multi
Media Park, No.1027 Chang
Ning Rd, Chang Ning District,
Shanghai, CHINA 200050
TEL: +86 021-5212-7942
URL: www.nidek-china.cn

NIDEK SINGAPORE PTE. LTD.
51 Changi Business Park
Central 2, #06-14, The
Signature 486066,
SINGAPORE
TEL: +65 6588 0389
URL: www.nidek.sg