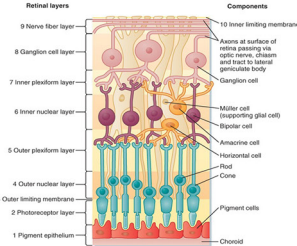
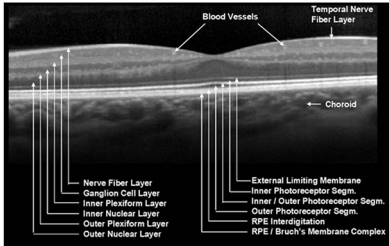


NIDEK RETINA SCAN DUO OCT

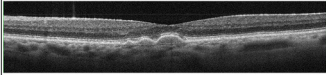
'SEEING MORE THAN BEFORE'



COMMON CONDITIONS SEEN WITH THE OCT

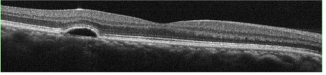
DRUSEN / DRUSENOID PED

Always based at the RPE / Bruch's Complex, Drusen cast no shadows. They tend to be hyper reflective. They show up at the RPE/BM on the En Face scans.



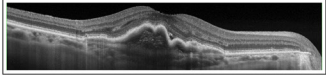
SEROUS PED

Pigment Epithelial Detachments occur when serous fluid lifts the whole Retina from Bruch's membrane. If BM is ever visible separately, this is always pathological. Serous fluid is dark (hypo-reflective) and casts no shadow.



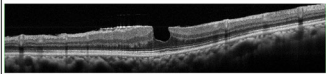
FIBRO-VASCULAR PED

Containing both hypo and hyper reflective elements and casting some shadow, these PED's show a risk of exudative AMD or neo-vascularisation and need to be referred for WET AMD.



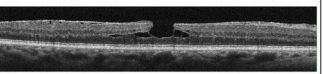
ERM / PSEUDO-MACULA HOLE

Epi Retinal Membranes are extremely common (usually post PVD). They can cause Traction and can lead to pseudo holes and lamellar holes. Normally, they are innocuous and don't require referral unless VA has dropped significantly or the Px has symptoms.



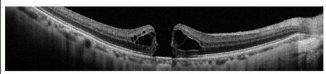
LAMELLAR HOLE

Caused by ERM's, lamellar holes are similar in appearance on the colour fundus to pseudo holes, but on the OCT, you can see there is separation of retinal layers not seen in a true pseudo hole. Often, monitoring is the best option.



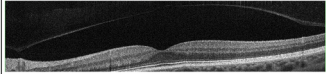
FULL THICKNESS MACULA HOLE

Full thickness holes are normally as a result of Vitreo Macula Traction (VMT). Sometimes, CMO (cystoid macula oedema) can lead to the same problem. Referral is very much necessary.



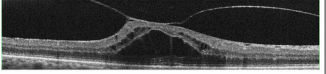
PVD (POSTERIOR VITREOUS FACE DETACHMENT)

PVD's are very common. Often they will be asymptomatic, but sometimes they can cause floaters and distortion. They can occur post VMT and may pull some of the retina with them (Operculum).



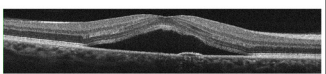
VMT (VITREO MACULA TRACTION)

Usually preceding PVD, this is where the vitreous is pulling on the retina and causing lifting. Full detachment may occur, or a hole may develop in the retina.



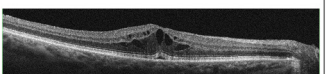
CSR (CENTRAL SEROUS RETINOPATHY)

Here, you can see there is SRF (sub retinal fluid) present, lifting the neuro sensory retina. Typically affecting males (10:1 ratio male to female), they now require referral within one month according to LOCSU.



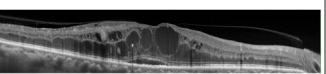
CMO (CYSTOID MACULA OEDEMA)

Classically, CMO is a post cataract surgery complication, but ultimately, it describes intra retinal cysts filled with serous fluid, which can occur as part of other retinal conditions.



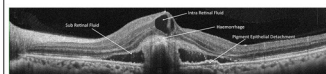
DMO (DIABETIC MACULA OEDEMA)

Notice the 'turbid' fluid in some of the cystic spaces. This is more indicative of blood leakage / plasma and you can see hyper reflective spots casting shadows, which are haemorrhages.



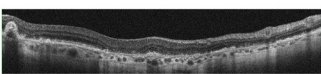
WET AMD

There is an active haemorrhage present centrally here, this is hyper reflective and casting a shadow. There is sub retinal fluid as well as intra retinal fluid and a PED. Urgent Referral would be warranted in a case like this.



GEOGRAPHIC ATROPHY

Where there is 'reverse shadowing' in the choroid (also known as a window defect), this indicates loss of RPE, which typically occurs in geographic atrophy in later stage dry AMD. Normally, referral would be inappropriate.



KERATOCUS (KC)

Here you can make out the Corneal cross section of the patients Cornea. It is rare to be able to actually diagnose KC with OCT, but the Pachymetry Maps can also aid with corrected IOPs and the Anterior Chamber Angles can also be measured, for Glaucoma checks.

